

# Pulmonary histoplasmosis simulating metastasis: two cases report and review of the literature

## *Histoplasmose pulmonar simulando metástases: relato de dois casos e revisão de literatura*

Artur S. Azevedo<sup>1</sup>; Nábia Maria M. S. Simão<sup>1</sup>; Ricardo M. C. Azevedo<sup>2</sup>; Frederico P. Barbosa<sup>1,3</sup>

1. Faculdade de Medicina de Campos. 2. Sociedade Brasileira de Cirurgia Torácica; Hospital Escola Álvaro Alvim.  
3. Hospital Escola Álvaro Alvim.

### ABSTRACT

**Introduction and objectives:** Systemic mycoses are of great importance in immunosuppression-associated conditions. Histoplasmosis can produce different symptoms that may simulate metastasis. We aim to demonstrate the importance of histopathological confirmation of lesions suggestive of metastases in patients with malignant neoplasm. **Cases report:** Two patients undergoing cancer treatment, whose chest computed tomography (CT) revealed pulmonary nodules, compatible with metastases. The lesions were biopsied, confirming histoplasmosis granuloma. **Conclusion:** In patients with cancer, clinical and radiological findings are not limited to metastatic dissemination of tumors, requiring histopathological confirmation of lesions suggestive of metastasis, excluding other diseases and preventing inappropriate treatment.

**Key words:** histoplasmosis; pulmonary nodules; granulomatous infection; malignant neoplasm.

### INTRODUCTION

The lungs are considered the second most frequent site of metastasis, mainly by hematogenous spread, usually presenting as multiple, bilateral nodules distributed peripherally<sup>(1)</sup>.

Although the primary diagnostic hypothesis for this image findings in patients with a malignant tumor, whether the metastatic disease, different etiologies can lead to similar conditions, including sarcoidosis, Wegener's granulomatosis, rheumatoid arthritis, Churg-Strauss syndrome, multiple hamartomas, and granulomatous infections, empirical treatment can be inefficient and harmful<sup>(1, 2)</sup>.

Histoplasmosis can manifest in different clinical forms that depend on the amount of fungal spores inhaled, the lung parenchyma anatomical conditions and host cellular immunity<sup>(2, 3)</sup>. When found in the form of pulmonary nodules, histoplasmosis can simulate primary or metastatic malignant disease in patients with a history of cancer, and lung lesion should therefore, be biopsied in those patients, in addition to performing histopathological examination and staining for specific microorganisms in order to make the differential diagnosis<sup>(1, 4, 5)</sup>.

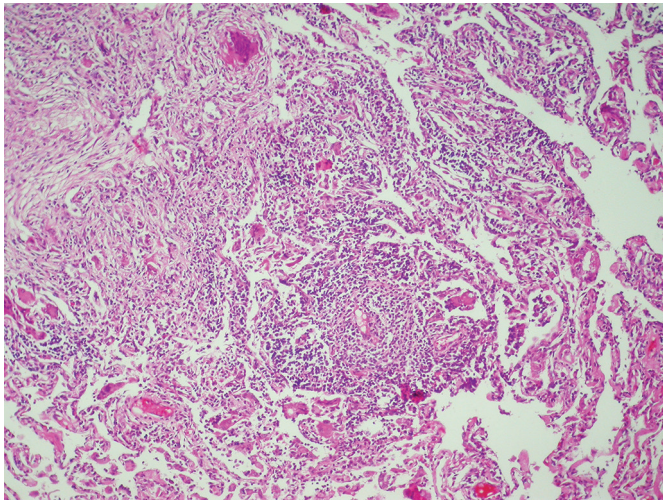
We describe two cases of patients with similar history of primary neoplasms of other sites presenting pulmonary granulomas that simulated metastases.

### CASES REPORT

#### Case 1

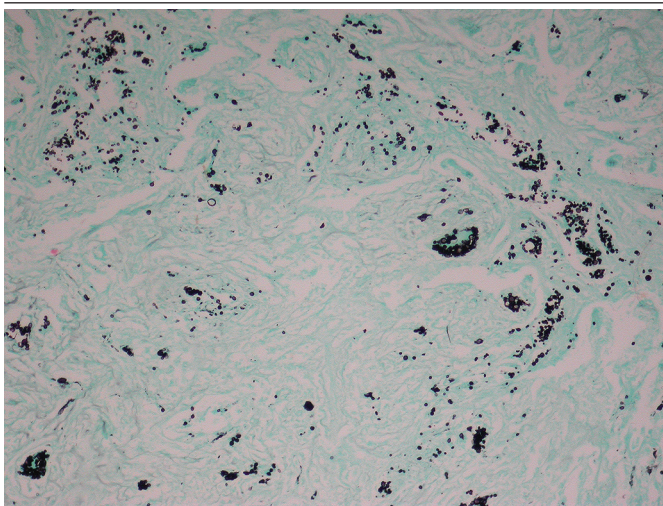
Female patient, 52 years old, with abdominal pain and jaundice was hospitalized and diagnosed with well-differentiated ductal adenocarcinoma of the pancreas, which was surgically resected. Chest computed tomography scans (CT) was performed for monitoring after about 1 year of treatment with chemotherapy, it was observed three small nodules with soft tissue density located in the subpleural region of the lower lobe of the left lung, and the emergence of two nodes with the same features in a comparative study two months after, and increase of other lesions, suggestive of secondary implants. After surgical resection of the pulmonary segment, histopathological analysis stained with hematoxylin-eosin (HE) showed focal obliteration of the lung architecture by dense cellular infiltrates, with nodular configuration, consisting of lymphocytes, histiocytes and multinucleated giant cells (**Figure 1**).

The diagnosis of histoplasmosis was confirmed by demonstration of small, round to oval multiple yeast, typical of *Histoplasma capsulatum*, in specific staining (Grocott's Methenamine Silver) (**Figure 2**).



**FIGURE 1** – Photomicrograph HE stain (10× objective): malformed granulomas with numerous multinucleated giant cells

HE: hematoxylin-eosin.

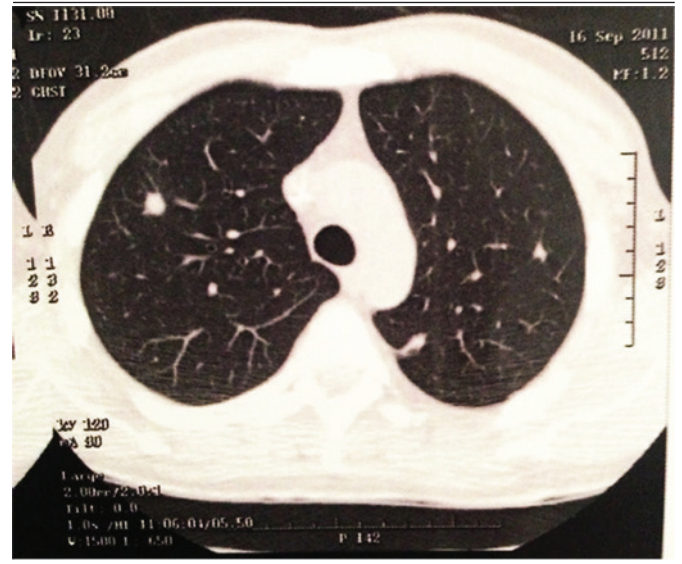


**FIGURE 2** – Photomicrograph with Grocott staining (10× objective): multinucleated giant cells with numerous microorganisms.

## Case 2

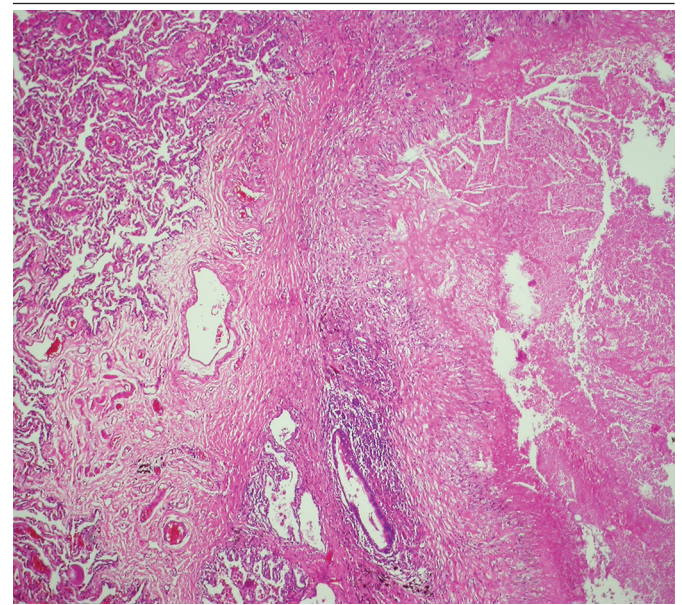
Male patient, 49 years old, with advanced gastric adenocarcinoma, underwent total gastrectomy, showed, after two years of evolution, in chest CT, five pulmonary nodules with soft tissue density in both upper pulmonary lobes (one in the right lung and four on the left), suggestive of metastasis (**Figure 3**),

but they showed no increase in CT performed three months later. Pulmonary segments that shown multiple epithelioid granulomas in histopathology stained by HE were resected, some were large, with abundant central caseous necrosis surrounded by epithelioid histiocytes, lymphocytes and fibrotic capsule of variable thickness (**Figures 4 e 5**). The specific staining (Grocott) showed numerous microorganisms consistent with *Histoplasma capsulatum*.



**FIGURE 3** – Chest CT scan: bilateral pulmonary nodules

CT: computed tomography.



**FIGURE 4** – Photomicrograph HE stain (10× objective): epithelioid granuloma with extensive central necrosis (right)

HE: hematoxylin-eosin.



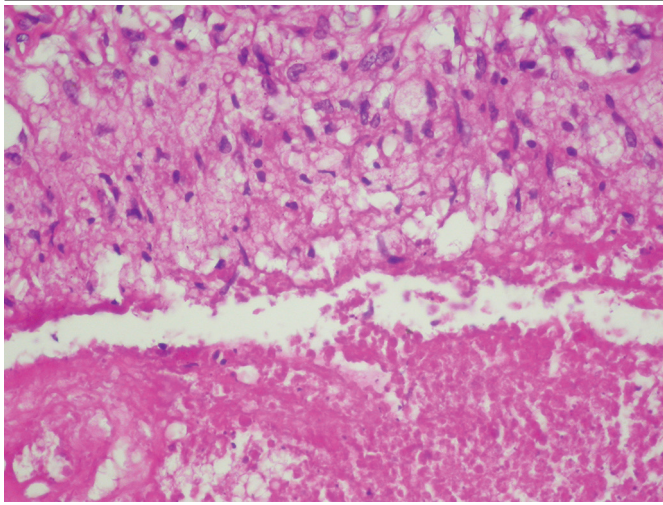


FIGURE 5 – Photomicrograph HE stain (10× objective): epithelioid cells (top) and caseous necrosis (below)

HE: hematoxylin-eosin.

Both patients were referred to the infectious disease specialist, who chosen itraconazole therapy over a period of one year, with progressive regression of the nodules.

## DISCUSSION

The term “immunocompromised” is primarily associated with acquired immunodeficiency syndrome (AIDS), chemotherapy, and bone marrow and solid organs transplantation. However, many other forms of immunosuppression may result in susceptibility to fungal infection, including primary immune deficiencies, chronic immunomodulatory therapy, very young or elderly patients, diabetes, chronic alcohol abuse, malnutrition, or other chronic wasting disease<sup>(6)</sup>.

Although *Candida* and *Aspergillus* species represent a majority of fungi diagnosed in the immunocompromised population, other fungi have been shown to be severe and common pathogens. The microorganism to which the patient becomes susceptible varies according to several factors, including the underlying disease, the degree of immunosuppression, and environmental factors<sup>(6)</sup>.

Infections are the most frequent complications in immunocompromised patients, and endemic mycoses are very important in the morbidity and mortality of these individuals, and attention should be given to patients with cancer treated with chemotherapy<sup>(6)</sup>.

Histoplasmosis is a disease caused by the thermal dimorphic fungus *Histoplasma capsulatum* var. *capsulatum*

(*H. capsulatum*), which can produce a wide spectrum of clinical manifestations, varying from complaints of self-limiting influenza-like illness, such as fever, cough and headache, to insidiously progressive infections<sup>(3,7)</sup>.

Chronic histoplasmosis is characterized by several months of development, which may cause the histoplasmosis as residual lesion of primary pulmonary disease, commonly found as asymptomatic pulmonary nodule in patients undergoing screening tests for other reasons<sup>(7)</sup>.

Pulmonary nodules has as main differential diagnoses neoplasms and granulomatous diseases, therefore, when dealing with a patient with multiple pulmonary nodules, the main measure is to differentiate the lesions as benign or malignant nature. Although such infections should be considered in the differential diagnosis, malignancy is placed as first hypothesis based on the nonspecificity of radiological findings and clinical manifestations, especially in patients with neoplasm previously diagnosed<sup>(1,2,5)</sup>.

The presence of multiple pulmonary nodules is a condition that often causes difficulties in diagnostic investigation, including as other hypotheses: sarcoidosis, Wegener’s granulomatosis, benign tumors, rheumatoid arthritis, Churg-Strauss syndrome, and multiple hamartomas<sup>(1)</sup>. In this study, the two cases presented simulated lung metastases in imaging tests; the diagnosis of fungal granulomatous disease was confirmed by histopathological examination, in agreement with the literature.

Although there are some imaging aspects that can help differentiate between benign and malignant conditions, the clinical and radiological manifestations of pulmonary lesions in infectious diseases (especially granulomatous) and malignancies are not sufficient for safely confirm the differential diagnosis, since it is not possible to find boundary features<sup>(1,5)</sup>.

The nodule stability, or the lack of size increase for two years, is widely accepted as the most reliable criteria for the classification of pulmonary nodules as benign. However, other studies show that this criterion is not as reliable, especially in small tumors that even growing, show no detectable volume gain<sup>(1)</sup>.

The presence of calcification in the nodule is also accepted by many as a sign of benignity, suggesting granuloma or hamartoma. Calcification of lung metastases is a rare event and when present, is associated with osteogenic sarcoma, chondrosarcoma, synovial sarcoma. Other signs known as suggestive of benignity are advanced age, cavitation and smooth margins without invasion. Although together they have some value in guiding clinical reasoning, none of them have positive predictive value high enough to benignity<sup>(1)</sup>.

Aiming to make an accurate diagnosis of suspicious lesions, biopsy and histopathological examination are essential. In the case of histoplasmosis, the classic lesion is a nodule with abundant central necrosis, surrounded by a palisade of epithelioid histiocytes and a fibrous capsule of variable thickness, but HE staining does not allow the visualization of fungal elements, so that Gomori-Grocott's methenamine silver (GMS) staining is fundamental, which shows uniform and oval small yeast<sup>(2,8,9)</sup>.

Our report reinforces the fact that the clinical syndrome of neoplastic disease is not limited to malignancy, and granulomatous infectious diseases should be considered in the differential diagnosis in spite of CT images suggestive of secondary implants. The exclusion of histoplasmosis in the differential

diagnosis of pulmonary lesions can delay diagnosis process and allow the occurrence of severe manifestations<sup>(3)</sup>.

## CONCLUSION

---

The report of two cases of pulmonary histoplasmosis in the form of multiple nodules in patients with malignant neoplasms previously diagnosed and undergoing postoperative monitoring (one undergoing chemotherapy) shows the importance of histopathological study for the differential diagnosis of metastases and granulomatous infections, thus preventing inappropriate management of patients.

---

## RESUMO

**Introdução e objetivos:** Micoses sistêmicas assumem grande importância nas situações de imunodepressão. A histoplasmose pode produzir diversas manifestações clínicas, podendo simular metástases. Objetivamos demonstrar a importância da confirmação histopatológica de lesão sugestiva de metástase em portadores de neoplasia maligna. **Relatos dos casos:** Dois pacientes com neoplasias em tratamento, nos quais tomografias de tórax de controle revelaram nódulos pulmonares compatíveis com metástases. As lesões foram biopsiadas, confirmando-se granulomas por histoplasmose. **Conclusão:** Em portadores de malignidade, aspectos clinicorradiológicos não se limitam à disseminação das neoplasias, sendo necessária a confirmação histopatológica de lesões sugestivas de metástases, excluindo-se outras doenças e evitando-se tratamentos inadequados.

**Unitermos:** histoplasmose; nódulos pulmonares; infecção granulomatosa; neoplasia maligna.

---

## REFERENCES

---

1. Manoel WJ, Silveira Jr LP, Ferreira EC, Abreu Neto IP, Junqueira MGM, Paula EC. Condições pulmonares simulando metástases: relato de dois casos e revisão de literatura. *Rev Bras Cancerol.* 2008; 54(4): 351-7.
2. Unis G, Pêgas KL, Severo LC. Histoplasmoma pulmonar no Rio Grande do Sul. *Rev Soc Bras Med Trop.* 2005; 38(1): 11-4.
3. Bello AGD, Severo BC, Guazzelli LS, Oliveira FM, Hochhegger B, Severo LC. Histoplasmose simulando neoplasia primária de pulmão ou metástases pulmonares. *J Bras Pneumol.* 2013; 39(1): 63-8.
4. Bello AGD, Severo BC, Guazzelli LS, et al. Histoplasmosis presenting with multiple pulmonary nodules: a case mimicking radiological features of pulmonary metastasis. *Rev Inst Med Trop São Paulo.* 2013; 55(3): 209-11.
5. Bello AGD, Severo BC, Oliveira FM, Hochhegger B, Severo LC. Infecções que mimetizam câncer: avaliação retrospectiva e prospectiva de micoses e actinomicetoses. *Rev Patol Trop.* 2013; 42(4): 395-401.
6. Lamps IW, Lai KKT, Milner Jr DA. Fungal infections of the gastrointestinal tract in the immunocompromised host: an update. *Adv Anat Pathol.* 2014; 21(4): 217-27.
7. Mukhopadhyay S, Katzenstein ALA. Biopsy findings in acute pulmonary histoplasmosis: unusual histologic features in 4 cases mimicking lymphomatoid granulomatosis. *Am J Surg Pathol.* 2010; 34(4): 541-6.
8. Mukhopadhyay S, Gal AA. Granulomatous lung disease: an approach to the differential diagnosis. *Arch Patol Lab Med.* 2010; 134: 667-90.
9. Tan BB, Flaherty KR, Kazerooni EA, Iannettoni MD. The solitary pulmonary nodule. *Chest Journal.* 2003; 123(1): 89-96.

---

## MAILING ADDRESS

Artur Salgado de Azevedo  
Faculdade de Medicina de Campos; Avenida Alberto Torres, 217; Centro; Campos dos Goytacazes-RJ, Brazil; e-mail: fmc@fmc.br.